

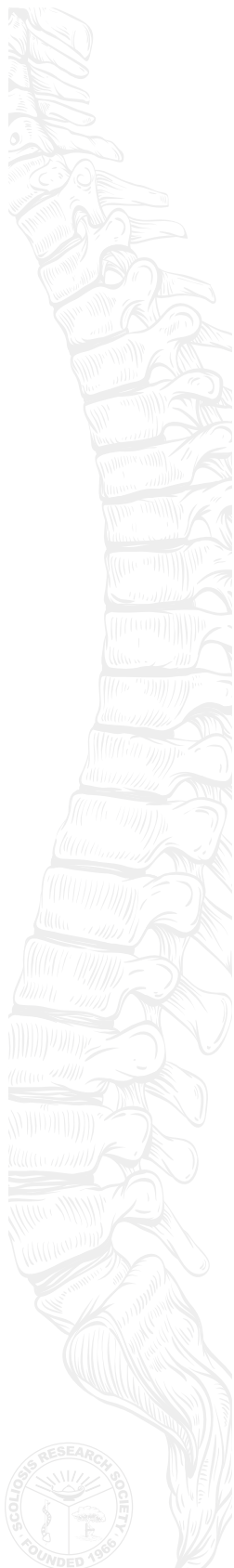Adolescent Idiopathic Scoliosis

A Handbook for Patients




Table of Contents



What is Scoliosis and Who Gets It?	2
Causes of AIS	2
Classification	2
Signs and Symptoms	3
Diagnosis	4
Natural History	4
Curve Progression	4
Non-Surgical Management.....	5
Surgical Treatment.....	6
FAQs.....	7
Glossary.....	9

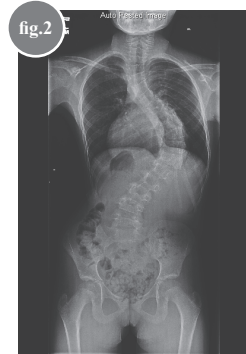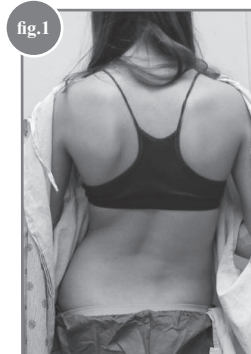What is Scoliosis and Who Gets It?



Everyone's spine has natural curves. These curves round our shoulders and make our lower back curve slightly inward. When viewed from the side, the upper back has a normal roundback or kyphosis, while in the lower spine there is "swayback", or lordosis. When viewed from behind, a spine normally appears straight but some people have spines that also curve from side to side and rotate. This condition of side-to-side spinal curvature is called scoliosis. Unlike poor posture, these curves can't be corrected simply by learning to stand up straight. On an x-ray, the spine of a person with scoliosis looks more like an "S" or a "C" than a straight line. (Fig 1,2)

A slight curvature may be normal. Scoliosis is present when the spine has one or more abnormal curves of greater than 10-15°, as measured on the x-ray by a physician.

In childhood, idiopathic scoliosis occurs in both girls and boys. However, as children enter adolescence, girls are five to eight times more likely to have their curves increase in size and require treatment.



Causes of AIS



Adolescent Idiopathic Scoliosis is a genetic condition, meaning it is inherited and a family may have more than one member with the diagnosis. The exact reason why the spine curves remains unknown (idiopathic). A difference in the rate of growth between the front and back of the spine is the leading theory.

Classification



Idiopathic scoliosis is categorized based on the age at which it begins.

Early Onset

- Infantile scoliosis occurs in children 3 years of age or less.
- Juvenile scoliosis occurs in children between the ages of 4 and 9 years of age.

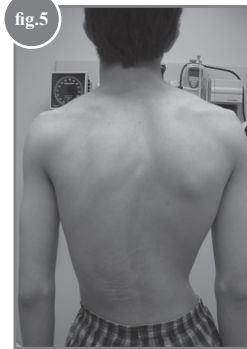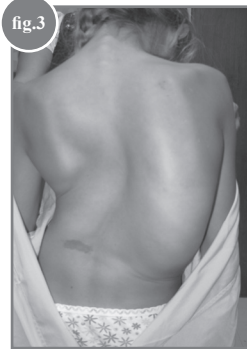Late Onset

- Adolescent idiopathic scoliosis occurs between 10 and 17 years of age. Adult idiopathic scoliosis is a slow increase in curvature that began during teenage years in an otherwise healthy individual and progresses during adult life.
- Adult degenerative scoliosis, also known as "de novo" scoliosis, begins in the adult patient due to degeneration of the discs, arthritis of the adjacent facet joints and collapse and wedging of the disc space.



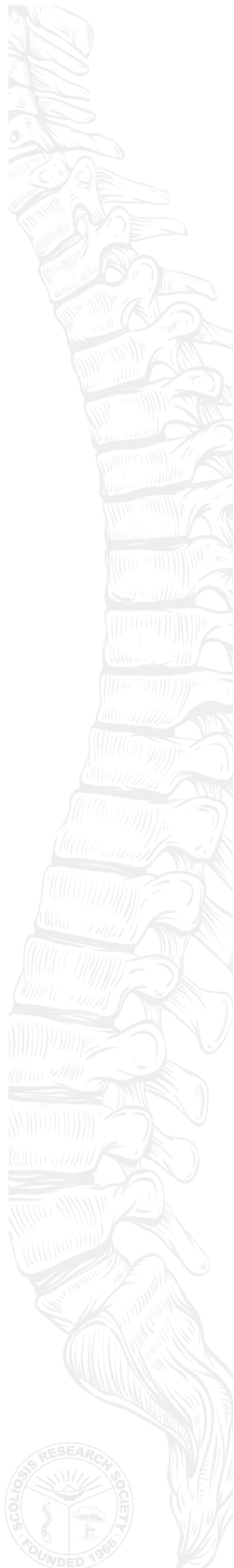Signs and Symptoms

Adolescent Idiopathic Scoliosis does not usually cause pain, neurological dysfunction such as weakness or numbness in the legs, or respiratory problems (shortness of breath). Most patients are highly functional and without any symptoms.



Most patients or parents note one or more of the following changes in the patient's appearance:

- Chest shifted to one side (Fig 3)
- Head not centered over bottom (Fig 4)
- One shoulder blade more noticeable than the other (Fig 4)
- Unevenness of the waist (Fig 5)
- Clothes hang unevenly (Fig 6)
- One shoulder higher than the other (Fig 7)
- One hip higher than the other (Fig 7)
- Unevenness of the front of the chest



Diagnosis



Adolescent Idiopathic Scoliosis is diagnosed based upon physical examination, medical history, including any family history of scoliosis, and full length spine radiographs. The doctor will ask the child to bend forward, which will show any spine abnormalities. This is called the Adams Forward Bend Test. (Fig 9) The doctor will check for other potential causes for the scoliosis. The size of the curve is measured in degrees as an angle on an x-ray, called the Cobb angle. (Fig10) The curve must be at least 10 degrees to be considered scoliosis. The curve may be in the upper (proximal thoracic), middle (main thoracic), and or lower (lumbar) spine.

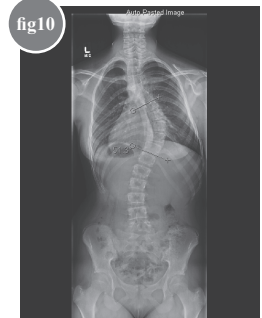
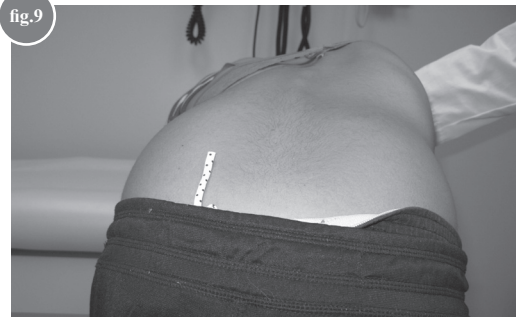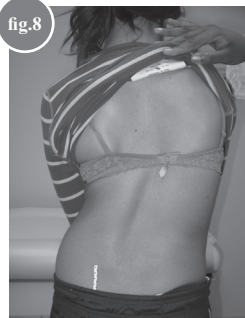
What should be done? Your doctor will look at several factors to choose the best treatment for your scoliosis. These factors would include the curve size, location of the curve in the spine, patient age and how much growth the patient has left in their spine. If the child is still growing, this will affect treatment options. The doctor will suggest treatment individualized to each specific child's need.

Figures —Diagnosis

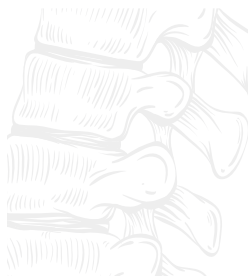Figure 8: Standing picture of patient in Figure 9.

Figure 9: Adams Forward Bend test

Figure 10: Cobb angle



Natural History



Most patients with mild scoliosis at skeletal maturity (the end of growth), can be assured that they will lead a normal life. There are no specific limitations on activity, including sports for patients with scoliosis. Female patients have typical pregnancies; concerns that their curve will progress during this period are unproven. For those patients with more significant curves (i.e. greater than 45-50 degrees), there is a significant likelihood that these curves will continue to worsen, even in adulthood. As a result of a progressive curvature, patients may experience pain, worsening appearance and a decrease in lung function with large curves over time.

Curve Progression



Although we do not know the cause of idiopathic scoliosis we do know that curves tend to progress based on two major factors: growth remaining in the spine and the curve size. Idiopathic scoliosis curves can get larger during growth of the spine especially during the rapid adolescent growth spurt. Age, the timing of the onset of menstrual periods in girls, the status of the growth plates of the pelvis and hand are all good predictors of how much spine growth is left. Your physician can review these parameters to estimate the risk of curve progression in your child. Even after your child stops growing, a large curve can get worse. Generally, curves in the thoracic spine greater than 45 or 50 degrees and lumbar curves greater than 35 or 40 degrees will progress even into adulthood. When significant growth remains AND the curve is larger than these thresholds, curve progression is 100 percent.

Non-Surgical Management



1. Observation: In a growing child, curves less than 25 degrees may be watched closely for progression. Larger curves in more mature teens may also be observed. Your doctor will make recommendations regarding the need for x-rays and how often to be seen.
2. Bracing: In the growing child, curves between 20-25° and 40-45° and for some smaller progressive curves, your doctor may recommend a brace to try to keep the curve from getting larger. Your doctor will advise which brace should be most effective in treating your child's curve.

There are many different varieties of braces and regimens for wearing (hours per day). There are custom molded braces (Wilmington, Milwaukee), off the shelf (Boston, Fig 11), night time only (Providence (Fig 12), Charleston (Fig 13)) and a flexible brace (Spine-cor) (Fig 14). Not all braces have been proven to be effective at this time.

Bracing will not make the spine straight and cannot always keep a curve from increasing. However there is strong evidence that patients who wear a well constructed brace for 13 hours or more per day will reduce the risk of progressing to surgery by 56%. Bracing can only be effective if the child is willing to wear the brace and there is routine follow-up with your physician. It is important to keep the child involved in their normal activities (athletics, dance, etc.), as instructed by your doctor, to benefit the child's overall well-being.

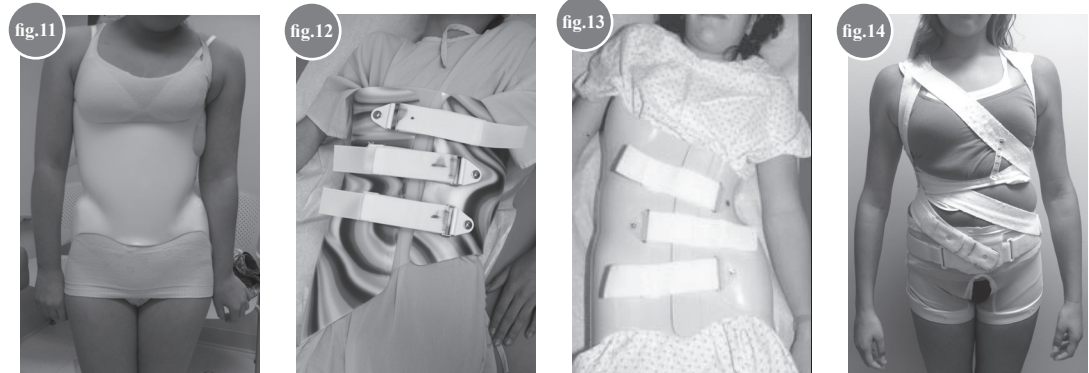
Figures—Non-Surgical Management

Figure 11: Boston Brace

Figure 12: Providence Brace

Figure 13: Charleston Bending Brace

Figure 14: Spine-cor Brace



3. Scoliosis Specific Exercises: Historically, physical therapy and exercises have been supplemental components of bracing programs to maintain core strength and gain flexibility. European based Physiotherapy Scoliosis Specific Exercises (PSSE) that involve auto correction, elongation, and chest wall expansion with integration of the “corrected” posture into daily life activities may be beneficial, but there is no evidence supporting PSSE substitution of bracing in treating progressive idiopathic scoliosis.
4. Alternative treatments: An Internet search of treatments for scoliosis will offer many sites promoting their “cures” for scoliosis. Some of these include chiropractic, yoga, and other forms of treatment. Although some of these methods may help in keeping one in better physical condition, there is no scientific proof that any of these alternative treatments are effective in treating progressive scoliosis.



Surgical Treatment

Surgery for scoliosis may be recommended when:

- A curve continues to worsen and there is significant growth left in the spine.
- Brace treatment has failed.
- A curve of the thoracic spine greater than 45 -50 degrees.
- A curve of the lumbar spine greater than 35-40 degrees.

Goals of surgery:

- Prevent worsening of the curve.
- Correct and balance the spine safely.

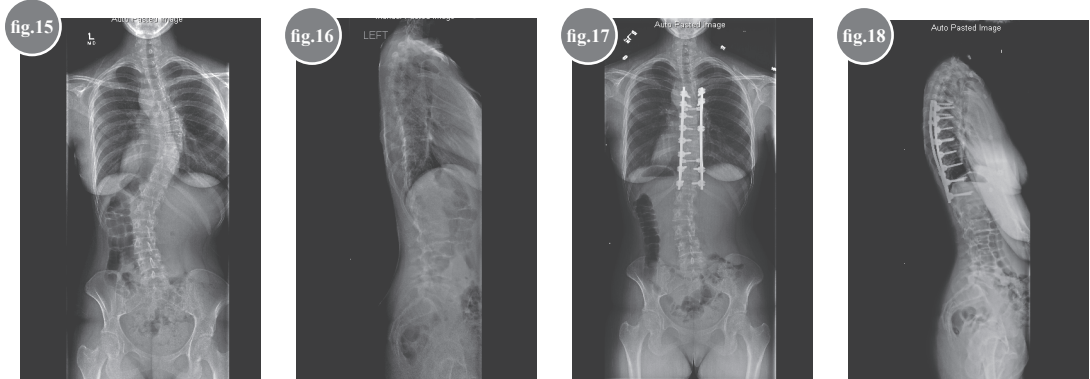
Figures—Surgical Treatment

Figure 15: Before surgery

Figure 16: Before surgery

Figure 17: After posterior spinal fusion

Figure 18: After posterior spinal fusion



Procedure:

- The most common surgical treatment for scoliosis is spinal fusion, also known as, arthrodesis. In this procedure implants are attached to your spine to hold the spine in its new corrected place until the vertebrae are fused. Implant anchors can include polyester bands, hooks, screws and wires. These anchors are attached to rods which hold the spine in its corrected position. The anchors and rods can be made of stainless steel, titanium or cobalt chrome. Titanium and cobalt chrome implants will allow the patient to have an MRI in the future if necessary. Spine implants can be attached to the front or side of the spine (anterior spinal fusion), or the back portion of the spine (posterior spinal fusion).
- In most cases, only a partial correction of the curve size can be completed. Sometimes dramatic corrections can be done, but in most patients complete correction of the curve is not possible or safe. Bone graft material is placed along the spine to help fuse the correction. There are several choices for bone graft, and these include local bone from the surgical area, bone taken from your pelvis, donor bone, and bone graft substitutes.

Recovery:

For patients undergoing surgery, a return to favorite activities afterwards is the norm. There will usually be a recovery period, as determined by your surgeon, for several months after surgery, followed by a gradual return to normal activities. While the surgeries are designed to treat the curvature without need for further surgery, younger patients who undergo this type of treatment occasionally require additional surgery as they age. Most patients report a significant improvement in their appearance and self-image, and report a high level of satisfaction with the results of their procedure.



FAQs



Does scoliosis cause back pain?

Adolescent scoliosis should not cause back pain, although larger curves may cause occasional discomfort. Adolescent patients with scoliosis get back pain at the same rate as their peers without scoliosis.

Can scoliosis curves get better on their own?

In most cases, idiopathic scoliosis curves do not straighten out on their own. Many children have slight curves that do not need treatment. In these cases, the children grow up to lead normal lives but their small curves never go away. Curves in children who are almost full grown may stop getting worse. If your child's spine is still growing, it is more likely that the curves will worsen.

What can I do to prevent my scoliosis from getting worse?

The only treatments that have been shown to affect idiopathic scoliosis are bracing and surgery. There is no evidence in the current medical literature that physical therapy, electrical stimulation, chiropractic care or other options have any impact on scoliosis curves.

Is it safe for my child to exercise and participate in sports?

Children with idiopathic scoliosis can participate in any sport as long as they have no backache associated with participation. It is always a good idea for children to stay physically fit with exercise.

Will my child be able to live a normal life?

Yes. People who have curves that do not require surgery are able to participate in the same activities and sports as people without scoliosis. There are rarely restrictions on any of their activities. The same usually applies to people who have had surgery for scoliosis. They can have the same jobs as people who have not had scoliosis surgery. They can usually do the same sports as before surgery. They should, however, contact their doctors before starting new activities (jobs or sports) to make sure they have no specific restrictions.

Could I have prevented it?

Because the causes of idiopathic scoliosis are not known exactly, it is difficult to determine how to prevent it. If idiopathic scoliosis is inherited, early screening and treatment may prevent the curve from worsening, but the patient cannot change their genes.

Does scoliosis run in families?

Yes, approximately 30% of adolescent idiopathic scoliosis (AIS) patients have a family history of scoliosis. There is currently a lot of research being done to investigate this genetic or hereditary link.

Does my child's bad posture cause the scoliosis?

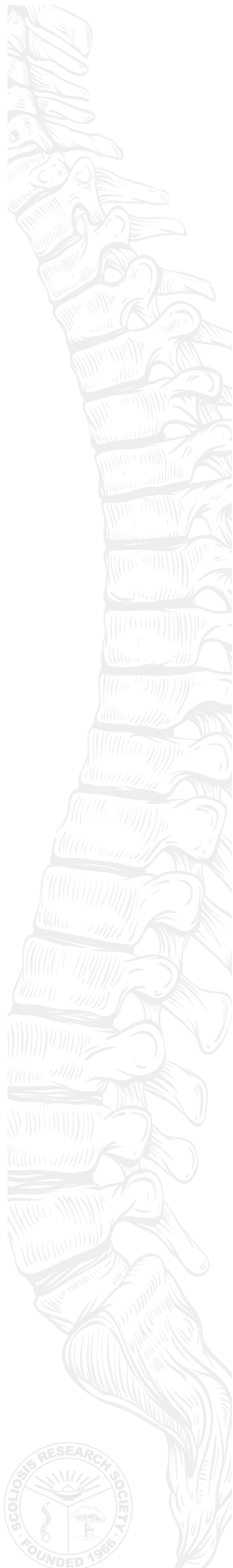No, bad posture does not cause scoliosis. The scoliosis may be the reason for your child's bad posture, especially if he or she tends to lean to one side.

Does a leg length difference cause or worsen the curve?

Leg length difference does not cause scoliosis. A large leg length difference can, however, make idiopathic scoliosis appear worse. In this uncommon circumstance, a shoe lift may be recommended.



FAQs



Do sports activities or heavy book bags cause scoliosis?

Sports activities or heavy book bags do not cause scoliosis or make a curve worse. Heavy book bags can be related to back pain, however. If back pain is present, it is advisable to lighten the load. Kids should carry lighter book bags with the straps over both shoulders. The American Academy of Pediatrics has recommended that the maximum weight of book bags be no more than 18% of the child's body weight.

How early should children be screened for scoliosis?

Scoliosis is often first detected during a regular check-up with the pediatrician. Children can be screened at any age, although idiopathic scoliosis is more commonly discovered during a child's growth spurt (10 to 15 years old). The Scoliosis Research Society recommends that girls be screened twice, at 10 and 12 years of age (grades 5 and 7), and boys once at 12 or 13 years of age (grades 8 or 9). A great deal of controversy exists as to the benefits of school screening.

Why didn't we notice it sooner?

In many cases, curves do not appear until the early teenage years. Small curves often go unnoticed until a child hits a growth spurt during puberty. Because scoliosis is rarely painful, children and their parents may not discover it until there are more obvious signs. In addition, adolescents tend to be modest. Many girls are self-conscious and tend to wear baggy clothing. It isn't until they wear more form-fitting clothes (bathing suits, t-shirts) that the curves are apparent. Also, adolescents may not see their pediatricians on a regular basis.

Is there genetic testing?

Yes, there is a genetic test to help determine whether a curve will get worse. However, the test is currently only for a select group of children. These are Caucasian girls between the ages of 9 and 13, with curves measuring 10 to 25 degrees. Researchers are working on improving the test to include all ethnic groups and all ages of children.

Does bracing work?

Several research studies show that bracing for scoliosis can keep your spinal curve from growing large enough to require surgery. A recent landmark study "Effects of Bracing in Adolescent Idiopathic Scoliosis" shows that bracing significantly decreased the progression of high-risk curves to surgery. The benefit increased with longer hours of brace wear. There are some cases, however, where the curve continues to grow even though a brace is worn. So bracing can work, but more research is necessary to optimize brace treatment.

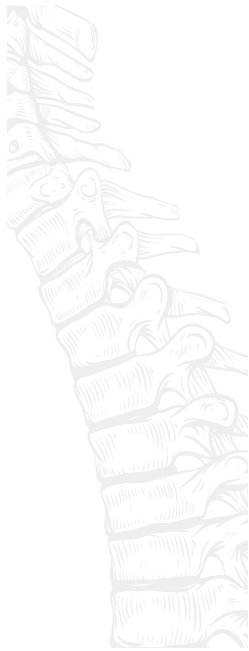Does surgery lead to permanent restrictions on activities?

No, most patients are able to return to all their favorite activities and sports. Most patients return to non-contact sporting activities (running, weightlifting, exercises) approximately 4 to 6 months after surgery. Before returning to all activities, including contact sports, the spine must be fully healed. It typically takes 6 to 12 months after surgery to obtain a solid fusion of the spine and get back to all activities.

What health problems might I have later in life as a result of scoliosis?

Problems with scoliosis later in life are related to the size and location of the curve in the spine. In general, people with curves less than 30 degrees have the same risks for back pain as people without scoliosis. People with larger, untreated curves (over 50 to 60 degrees) are more likely to develop back pain, particularly in the lower back.

FAQs



Will having scoliosis affect my ability to bear and deliver a child?

No, it should not. There have been many studies on scoliosis and pregnancy, and none have shown difficulties in childbearing in patients with scoliosis. There are no increases in fetal distress, premature deliveries or problems with delivery. In addition, pregnancy does not typically cause a significant increase in the degree of scoliosis in an unfused spine.

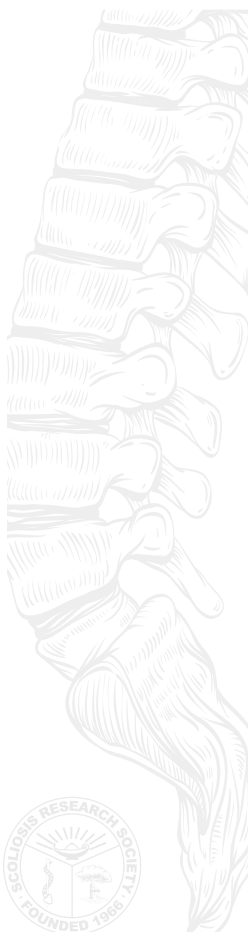Can I have an epidural in the future?

Yes, you can get an epidural as an anesthetic for delivery. Very severe curves may be technically difficult, but epidurals might still be possible. If you have had a spinal fusion, be sure your obstetrician and anesthesiologist know what levels of fusion have been performed.

Will the metal detectors go off in airport security after I have rods placed in my spine?

This depends on how sensitive the detector is, but it typically does not happen. A letter from your doctor explaining your implants may be helpful to have on hand. You may also need to show the healed incision on your back in the rare event that the detector goes off. For more information on this topic please visit, <http://tsa.gov/traveler-information/metal-implants>.

Glossary



Adolescent Scoliosis - Lateral spinal curvature that appears between ten and eighteen years of age.

Adolescent Idiopathic Scoliosis - Adolescent scoliosis in which the cause has not been established. Refer to Idiopathic Scoliosis.

Adult Scoliosis - Scoliosis of any cause which is present after skeletal maturity.

Anterior Spinal Fusion - A surgical technique which involves the removal of the intervertebral disc, and replacement with bone graft. Additional structural supports may be placed in the disc space, such as hard (cortical) bone grafts, metal or synthetic spacers, to maintain good spinal alignment

Apex of Scoliosis - The area of greatest curvature or displacement from the midline of the body.

Apical Vertebra - When referring to scoliosis, it is the vertebra with the greatest distance from the midline and has the most rotation.

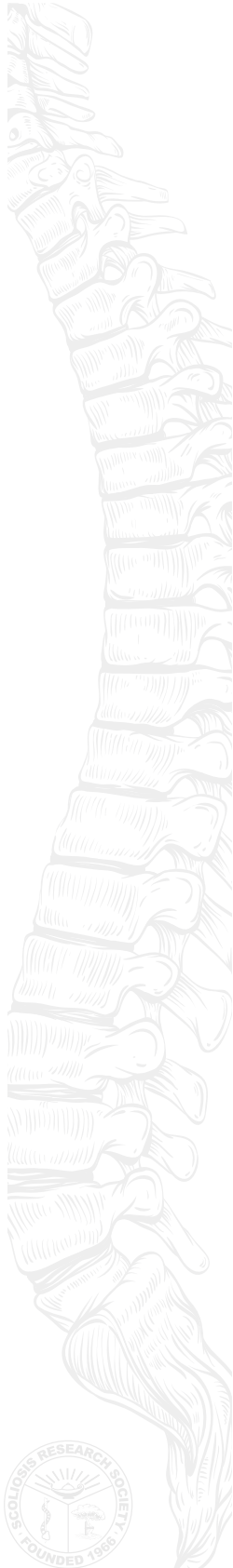Autologous Blood - Blood collected from a person for later transfusion to that same person. This technique is often used prior to elective surgery if blood loss is expected to occur. This may avoid the use of bank blood from unknown donors

Autotransfusion - The practice and technique of transfusing previously drawn autologous blood back to the same patient

Bone Graft - Human bone, which is harvested from one location in an individual and placed in another individual (allograft bone) or in a different location in the same individual (autogenous bone). A common place to take autogenous bone graft from is the anterior and posterior iliac crests (the hip bones)



Glossary



Cervical Spine - Seven spinal segments (C1-C7) between the base of the skull (occiput) and the thoracic spine. The normal cervical spine alignment is lordosis.

Compensatory Curve - In spinal deformity, a secondary curve located above or below the structural curvature, which develops in order to maintain normal body alignment.

Decompensation - In scoliosis, this refers to loss of spinal balance when the thoracic cage is not centered over the pelvis.

Double curve - Two lateral curvatures (scoliosis) in the same spine.

Double major curve - Describes a scoliosis in which there are two structural curves which are usually of equal size.

Double thoracic curve - A scoliosis with a structural upper thoracic curve, as well as a larger, more deforming lower thoracic curve and a relatively non-structural lumbar curve.

Fusion - The uniting of two or more bony segments.

Hysterical scoliosis - A non-structural deformity of the spine that develops as a manifestation of a psychological disorder.

Idiopathic scoliosis - A structural spinal curvature for which the cause has not been established. There is no evidence of underlying physical or radiographic pathology. This is the most common type of scoliosis.

Inclinometer - An instrument used to measure the angle of thoracic (rib) or lumbar (flank) prominence, referred to as the angle of trunk rotation (ATR).

Iliac Bone - A part of the pelvic bone that is above the hip joint and from which autogenous bone grafts are frequently obtained

Infantile scoliosis - A curvature of the spine that develops before three years of age

Juvenile scoliosis - Scoliosis developing between the ages of three and ten years

Kyphoscoliosis - A structural scoliosis associated with increased kyphosis (roundback).

Kyphosis - The normal forward curvature of the thoracic spine. A posterior convex angulation of the spine as evaluated from the side (roundback). Contrast to lordosis.

Lordoscoliosis - A lateral curvature of the spine associated with increased lordosis (swayback).

Lordosis - The normal mild anterior angulation (swayback) of the lumbar spine as evaluated from the side. Contrast to kyphosis.

Lumbar Curve - A spinal curvature whose apex is between the first and fourth lumbar vertebrae (also known as lumbar scoliosis).

Lumbar Spine - Five mobile segments of the lower back (L1 to L5). These are the largest of the vertebral segments and provide most of the bending and turning ability of the back, in addition to bearing most of the weight of the body.

Lumbosacral - Pertaining to the lumbar and sacral regions of the back.

Glossary



Lumbosacral Curve - A lateral curvature with its apex at the fifth lumbar vertebra or below (also known as lumbosacral scoliosis).

Nonstructural curve – description of a spinal curvature or scoliosis that does not have fixed residual deformity when checking the curve’s flexibility

Osteotomy - The surgical removal of a wedge or piece of vertebral bone to alter the alignment of the spine; may also be used in previously fused vertebrae to enable the surgeon to move them.

Pedicle - The part of each side of the neural arch of a vertebra which projects backward from the vertebral body. It connects the lamina with the vertebral body.

Posterior Spinal Fusion - A surgical technique which involves roughening or removing the hard bony surfaces (decortication) of the lamina(e), spinous processes, and facet joints, to stimulate two or more spinal bones (vertebrae) to heal together (fusion). Bone grafting with autogenous and/ or allograft bone is used to enhance the fusion process. Instrumentation (implants) may also be used

Primary Curve - The first, or earliest, curve to appear

Pseudarthrosis - An area of the spinal fusion where the bone did not heal (fuse). Often found with broken instrumentation and, in some instances increased pain, although not always.

Risser Sign - Used to evaluate skeletal and spinal maturity, this refers to the appearance of a crescent-shaped line of bone formation which appears across the top of each side of the pelvis on plain x-ray.

Sacral Spine - (Sacrum) - The curved triangular bone at the base of the spine, consisting of five fused segments of the lower spine that have four foramen on each side. The sacrum articulates (connects) with the last lumbar vertebra and laterally with the pelvic bones

Scoliometer - A proprietary name for an inclinometer used in measuring trunk rotation.

Scoliosis - Lateral deviation of the normal vertical line of the spine which, when measured by x-ray, is greater than ten degrees. Scoliosis consists of a lateral curvature of the spine with rotation of the vertebrae within the curve. Rotation of the vertebrae also occurs which produces the rib cage and flank muscle asymmetry.

Spinal Canal - The long canal between the vertebral bodies anteriorly and the lamina and spinous processes posteriorly through which the spinal cord passes. The spinal cord and nerve roots extend to the level of the second lumbar segment in adults. Below this level are numerous nerve roots from the spinal cord that resemble a horse’s tail and is referred to as such (cauda equina). The thick outer covering of the spinal cord is called the dura.

Spinal Fusion - A surgical procedure of stabilizing (permanently join to prevent motion) two or more vertebra by bone grafting. Can be done from the front (anterior), back (posterior), or as a staged procedure (first anterior and then posterior), usually with instrumentation.

Spinal Instrumentation - Metal implants fixed to the spine to improve spinal deformity while the fusion solidifies (becomes solid bone). This includes a wide variety of rods, hooks, wires, and screws used in various combinations

Glossary



Structural Curve - A segment of the spine that has fixed (nonflexible) lateral curvature.

Thoracic (Dorsal) Spine - Twelve spinal segments (T1-T12) incorporating the 12 ribs of the thorax. Other than a slight increase in size from top to bottom, they are fairly uniform in appearance.

Thoracic Curvature - Any spinal curvature in which the apex of the curve is between the second and eleventh thoracic vertebrae.

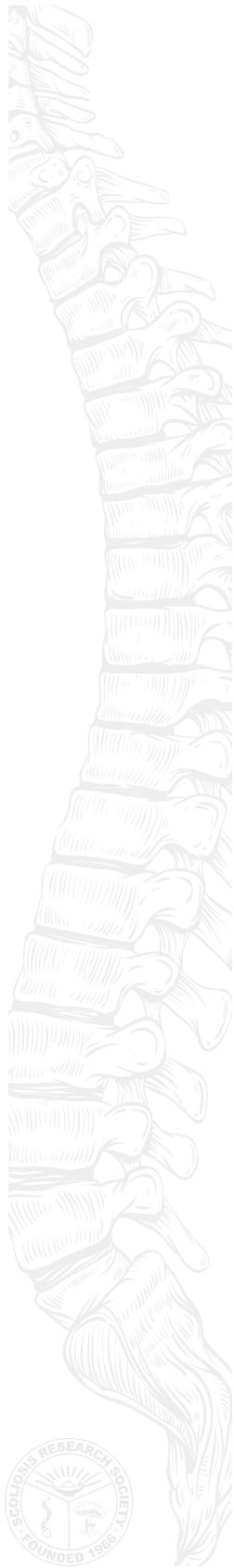Thoracolumbar Curve - Any spinal curvature that has its apex at the twelfth thoracic or first lumbar vertebra.

Thoracolumbosacral Orthosis (TLSO) - A type of brace immobilizing the thoracic lumbar and sacral spine. This may be used to help stabilize/ prevent progression of scoliosis curve(s) while a child is growing, or to immobilize the spine after surgery.

Vertebra - One of the 33 bones of the spinal column. A cervical, thoracic, or lumbar vertebra has a cylindrically shaped body anteriorly and a neural arch posteriorly (composed primarily of the laminae and pedicles as well as the other structures in the posterior aspect of the vertebra) that protect the spinal cord. The plural of vertebra is vertebrae.

Vertebral Column - The flexible supporting column of vertebrae separated by discs and bound together by ligaments.

Your support can change the lives of others with spinal deformities



Please consider a donation to SRS.

100 percent of all contributions and donations to the Scoliosis Research Society's (SRS) Research, Education Outreach (REO) Fund are used entirely for research, outreach programs, and educational scholarships and fellowships seeking improved treatments, the causes and possible prevention of spinal deformities. Operating funds for SRS come from membership dues, educational meetings and courses, publication sales and other sources.

With your support, SRS can continue to support and offer necessary educational opportunities, beneficial research grants and maintain effective advocacy efforts that will change the lives of those living with spinal deformities.

If you would like to make a donation to the Scoliosis Research Society, please fill out the form below and mail it to:

Scoliosis Research Society
555 East Wells Street, Suite 1100
Milwaukee, WI 53202-3823 USA

Please make checks payable to Scoliosis Research Society.

If you would like to make your donation online, please go to www.srs.org/support/donate_now.htm

YES! I would like to donate to the Scoliosis Research Society (SRS) to help continue in fulfilling its mission to improve the lives of patients with spinal deformities!

Enclosed is my gift of: \$10, \$20, \$35, \$50, \$100, \$150, Other _____

This gift is (in honor/in memory) of _____

Please make checks payable to Scoliosis Research Society. If you would like to make your donation online, please go to www.srs.org/support/donate_now.htm

Credit Card Information

Name

Address City State Zip Country

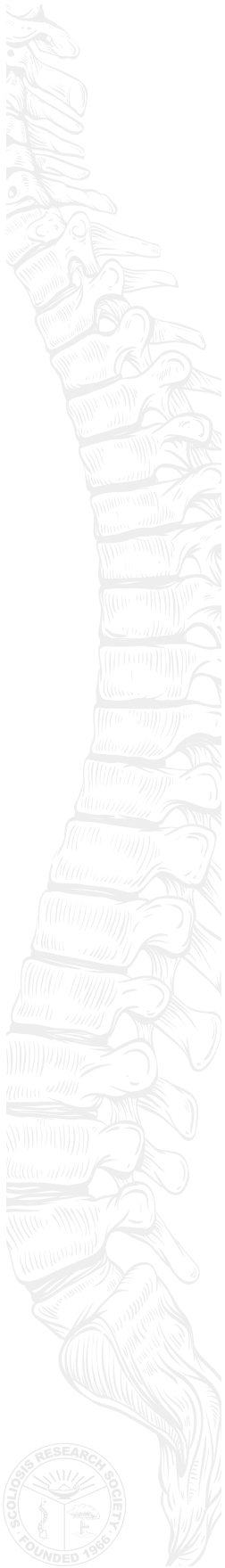Phone Email

Visa, MasterCard, American Express, Discover

Card Number

Exp. Date (MM/YY) Security Code

Signature



Contributing to the REO Fund

Thank you for considering a donation to the Scoliosis Research Society. All donations made to SRS through the REO Fund are recognized through the SRS Levels of Giving. Levels of Giving can be achieved over a lifetime. Recognizing that donors based in the U.S. receive significant tax benefits for charitable donations; corresponding recognition levels have been established for international donors. The REO Fund provides donors the opportunity to donate through various options, from individual donations, pledged giving over five years or even deferred gifts.



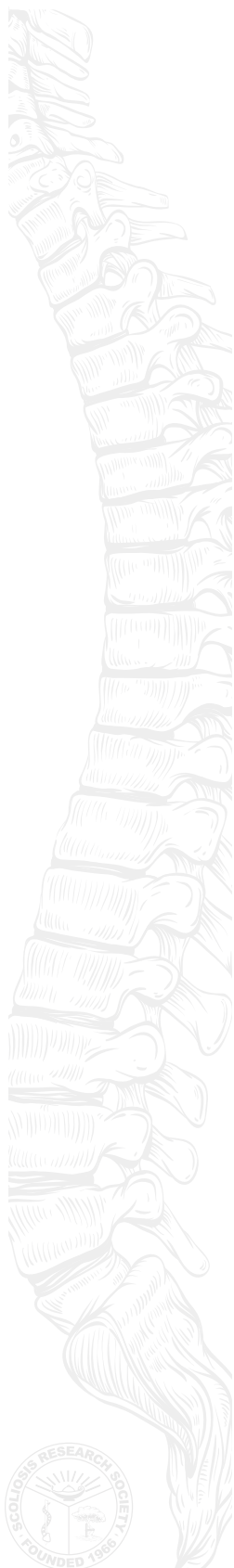LEVEL OF GIVING	DONATION AMOUNT	
	UNITED STATES	OUTSIDE U.S.
CONTRIBUTING	\$100 - \$4999	\$50 - \$2499
SUSTAINING	\$5000-\$9999	\$2500-\$4999
BENEFACTOR	\$10,000-19,999	\$5000-\$9999
PRESIDENTS	\$20,000-\$39,999	\$10,000-\$19,999
PRESIDENTS ELITE	\$40,000-\$99,999	\$20,000-\$49,999
FOUNDERS	\$100,000-\$499,999	\$50,000-\$249,999
LEGENDS	\$500,000-\$999,999	\$250,000-\$499,999
LEGENDS ELITE	\$1 Million or more	\$500,000 or more

Pledges can be spread over a maximum of five years per level. For example, members outside the U.S. can reach Benefactor Level with payments of \$1,000 per year for five years or \$2,000 over five years to achieve Presidents level.

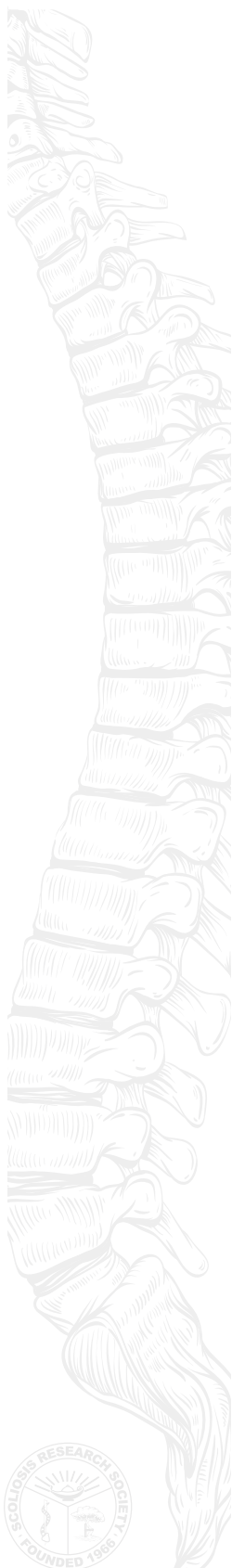
Individual gifts can be made at any time, in any denomination and will accumulate over the span of the donor's life. Levels of Giving are achieved as the donor continues to give.

Deferred giving A U.S. life insurance gift of \$100,000 will earn the donor a place in the Founders Recognition Level.

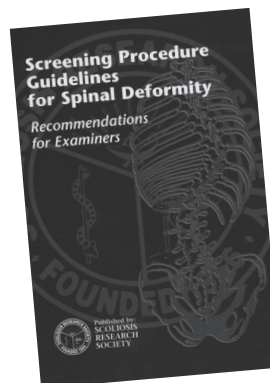
The SRS is a 501(c)(3) organization, tax identification # 23-7181863. Your gift to the SRS REO fund is fully tax-deductible to the extent allowed by law.



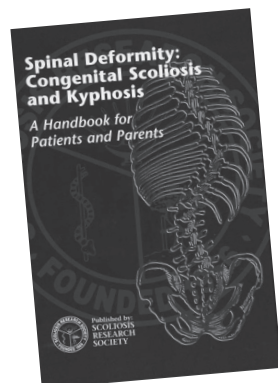
Other brochures available through the Scoliosis Research Society



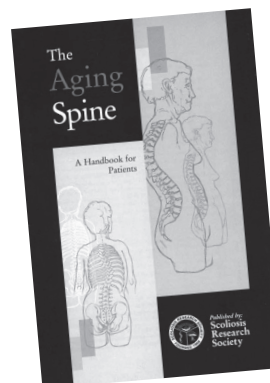
Spinal Deformity: Scoliosis and Kyphosis
A Handbook for Patients
12-page brochure discusses signs and causes of scoliosis and kyphosis, indications for treatment, treatment options, commonly asked questions and a glossary of terms. Illustrated.



Screening Procedure Guidelines for Spinal Deformity: Scoliosis and Kyphosis
Recommendations for Examiners
7-page brochure covers reasons, organization and procedures for spinal screening. Signs of spinal deformity, as seen in both standing and forward bending positions, are illustrated and discussed. Includes sample screening form.




Spinal Deformity: Congenital Scoliosis and Kyphosis
A Handbook for Patients and Parents
12-page brochure discusses signs and causes of congenital spinal deformities, associated conditions, treatment options, and a glossary of terms. Illustrated.



The Aging Spine
A Handbook for Patients
An 8-page brochure discusses causes and treatments of osteoporosis and compression fractures, and osteoarthritis and other degenerative conditions of the spine.



To order additional brochures please contact: info@srs.org



Scoliosis Research Society
555 East Wells Street, Suite 1100
Milwaukee, WI 53202-3823 USA

Phone: (414) 289-9107
Fax: (414) 276-3349
Email: info@srs.org
Web: srs.org