


Early Onset Scoliosis

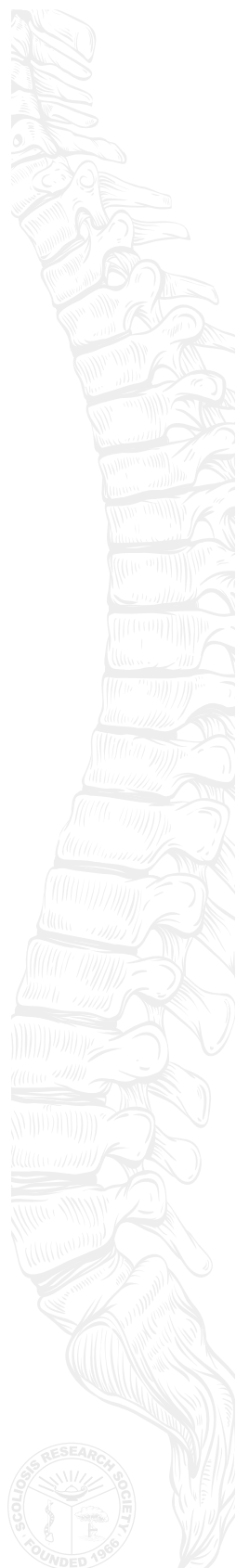Patient Resource Guide



The SRS is an international association.

SCOLIOSIS RESEARCH SOCIETY | 555 EAST WELLS STREET, SUITE 1100 | MILWAUKEE, WI 53202-3823 USA

Table of Contents



Introduction	3
Infantile Idiopathic Scoliosis	3
Juvenile Idiopathic Scoliosis	4
Congenital Scoliosis	5
Neuromuscular Scoliosis	6
Syndromic Scoliosis	7
Non-Surgical Management.....	8
Surgical Treatment.....	9
Summary	15



Introduction



Early onset scoliosis (EOS) is a lateral (side-to-side) curve of the spine that is diagnosed before age 10. All patients with EOS are not the same. While some cases are “idiopathic” (no known cause), others are associated with an underlying condition that will affect how the patient is treated. While it is not possible to review all the different types of EOS, it is helpful to divide patients into categories when discussing treatment. As always, your surgeon can help you understand the specific issues that apply to your child.

In some forms of EOS, the spine has normal shaped bone but grows in a curved fashion. This category includes:

- Idiopathic cases (including “infantile” (0-3 years old) or “juvenile” (4-10 years old) scoliosis)
- Syndromic cases (those associated with an underlying disease, such as Marfan Syndrome or Ehlers Danlos syndrome)
- Neuromuscular cases (those associated with a neuromuscular condition, such as Spinal Muscle Atrophy)
- Others (associated with prior surgery, such as heart surgery)

The other form of scoliosis is called “congenital,” where the bones are not formed normally, causing a curvature of the spine. There can be associated abnormalities of the rib cage as well. When this causes difficulties breathing, it is known as “thoracic insufficiency syndrome.”

Initial Evaluation-Diagnosis and Prognosis

When evaluating a patient with potential early-onset scoliosis, your doctor will first take a detailed history and perform a thorough physical assessment. After this, the next step is obtaining X-rays of the spine and neck. Computed tomography (CT) and magnetic resonance imaging (MRI) scans are also sometimes done to get a three-dimensional view of the spine and how it is positioned in the body.

In children less than 3 months of age, sometimes an ultrasound can be helpful to look at the spinal cord. Your doctor may also recommend an ultrasound of the kidneys or investigations related to the heart, since the kidneys and heart are formed at the same time as the vertebrae. Something that affects the spine may also affect these other organs, particularly when there is abnormal formation of the bones of the spine.

Infantile Idiopathic Scoliosis



Introduction

Infantile *idiopathic* scoliosis is a type of scoliosis that is first diagnosed in a child between birth and 3 years old. *The term idiopathic means the cause is unknown and implies that the child is otherwise healthy.* Congenital spinal anomalies (i.e., misshapen and connected vertebrae) are also often diagnosed during this period, but are not included in the infantile idiopathic category. Most infantile idiopathic scoliosis curves are left-sided curves in the thoracic (chest) area. It is more common in boys than girls. Many infants with infantile idiopathic scoliosis are healthy and normal, and simply have a small curvature of the spine. In some patients, however, there is an increased association with hip dysplasia, mental retardation, and congenital heart disease.



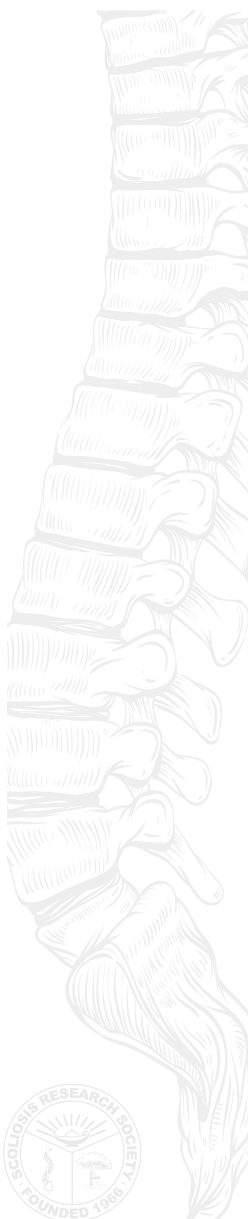Evaluation

Your spine surgeon may suggest a magnetic resonance imaging (MRI) study in a case of infantile idiopathic scoliosis that is not getting better, to determine if there are any abnormalities of the spinal cord or spinal column that are causing the deformity. The decision to get an MRI in an infant is not a simple one. Generally, sedation or general anesthesia, with their associated risks, is necessary to relax the child so that good images can be taken. Because of these factors, sometimes an MRI is put off until the child is older.

Prognosis

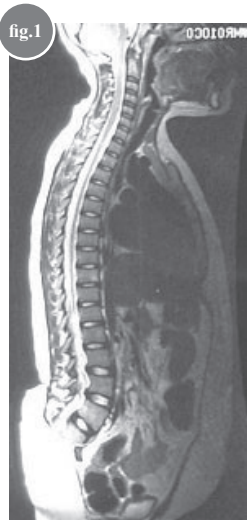Many infantile curves will resolve without treatment. *Children who have significant curves with proven or anticipated progression require treatment. Today, the wide range of available interventions allows an individualized therapeutic approach.*

Juvenile Idiopathic Scoliosis



Introduction

Juvenile idiopathic scoliosis is a type of scoliosis that is first diagnosed between the ages of 4 and 10. This category makes up about 10% to 15% of all idiopathic scoliosis in children. At the younger end of the spectrum, boys are affected slightly more than girls and the curve is often left-sided. Towards the upper end of the age spectrum, the condition is more like adolescent idiopathic scoliosis, with a predominance of girls and right-sided curves.



Evaluation

Just as described for infantile scoliosis, your spine surgeon may choose to order an MRI. This decision is based on the presentation of the curve, findings on physical examination, and X-ray features. As a rule of thumb, about 20% of children who are younger than 10 and who have a curve greater than 20° will have an underlying spinal condition. There is a particularly high incidence of Arnold-Chiari malformation (in which the lower part of the brain extends into the cervical spine) and syringomyelia (cyst in the spinal cord) associated with juvenile scoliosis, which might be detected on an MRI of the entire spine. (Figure 1) If something is seen on the MRI that could be causing your child's scoliosis, your doctor will probably refer you to a neurosurgeon. On occasion, a neurosurgical intervention may help correct the curvature.

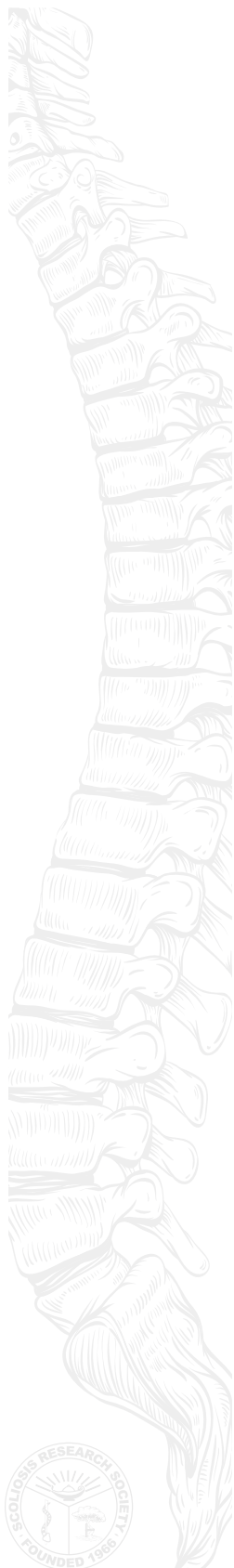Figure 1 – MRI of the entire spine. In this case, a syringomyelia was detected.

Prognosis

Juvenile curves that reach 25-30° tend to continue to worsen without treatment. Bracing is often used to manage these curves, but many children in the juvenile age range go on to require surgical treatment.



Congenital Scoliosis



Introduction

The term “congenital scoliosis” refers to a spinal deformity caused by vertebrae that are not properly formed. This occurs very early in development--in the first six weeks of embryonic formation and often before the mother knows she is pregnant, and the cause is not known. Congenital scoliosis does not seem to run in families. Genetic studies to date have not yielded much evidence that this condition can be inherited. Although congenital scoliosis is often discovered during the infant or toddler period, in some children it does not appear until their adolescent years.

Spine surgeons describe congenital spinal anomalies based on which part of the vertebra is malformed or connected. Depending on the structure of the anomaly, the child may exhibit scoliosis (a curve to the right or left), kyphosis (rounded back), or lordosis (sway back). However, not all congenital anomalies fit neatly into these categories. There are often elements of more than one deformity, particularly scoliosis and kyphosis, occurring together.

Spine surgeons may refer to the spine anomaly as a “failure of segmentation.” This means that one or more vertebrae are abnormally connected together on one side. This connection will slow growth on that side of the spine. Normal growth on one side with slowed growth on the other leads to a spinal deformity. “Failure of formation,” the most common type of congenital problem, means that the normal shape of the vertebra is disrupted (Figure 2). On an X-ray view taken from front to back, these vertebra will look like triangles instead of rectangles. Regular X-rays, though, only show a two-dimensional picture of what is really a three-dimensional problem. The abnormally shaped vertebra may cause a wedge in the front, back, either side, or a combination, tilting the spine at that level. Spine surgeons often use descriptive terms to describe how much growth potential may be in the congenital anomaly. The term “fully segmented” means that there is a growth plate and a disk on both the top and bottom of the abnormal vertebra. “Semi-segmented hemivertebra” have a disk and growth plate either above or below. “Non-segmented hemivertebra” are fused to the vertebra above and below. Since non-segmented hemivertebrae have no growth plates, the curves they cause are much less likely to progress than those due to semi-segmented hemivertebrae, which are less likely to progress than a fully segmented hemivertebra. A “block vertebra” means that there is a missing disk space. Block vertebrae essentially have no growth potential and therefore rarely cause a progressive deformity.

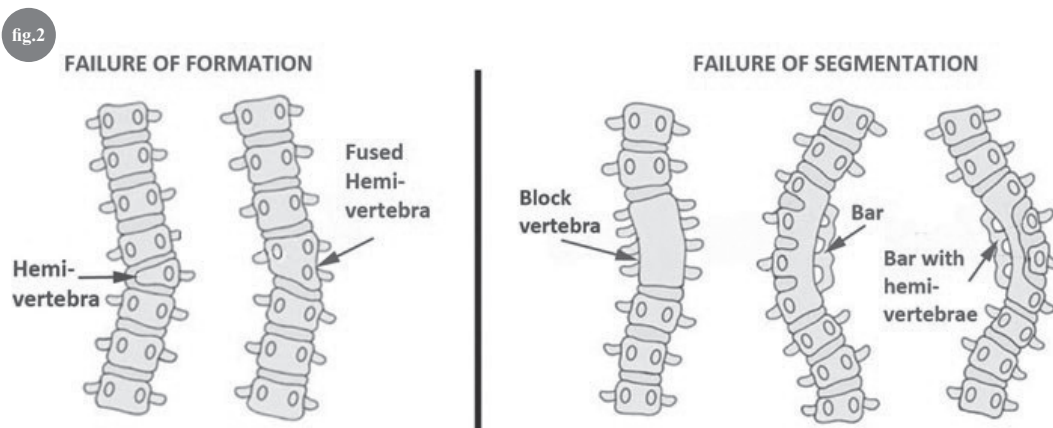


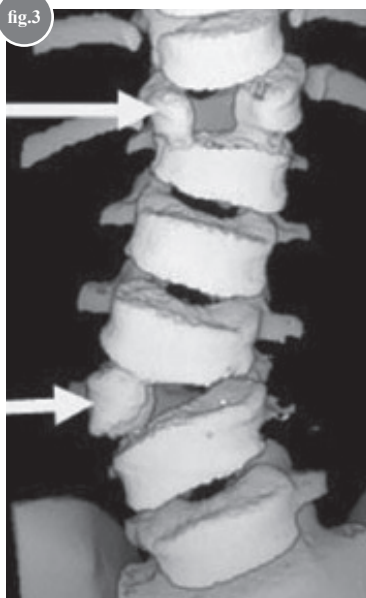
Figure 2 – Types of congenital scoliosis.





Evaluation

After the history and physical examination, the next step in evaluating congenital scoliosis is obtaining X-rays. Good quality Posteroanterior(Back-to-front) and lateral (from the side) X-rays are necessary. X-rays of the neck should be taken to look for abnormal vertebrae in this area. The three-dimensional structure of the congenital anomaly may be best seen on a CT scan with reconstruction (this study is usually done as part of a preoperative planning, Figure 3). An MRI is very valuable to characterize the congenital anomaly and to be certain that there are no associated anomalies of the spinal cord. In children younger than 3 months (before the vertebrae ossify and harden), an ultrasound examination can scan the spinal cord for abnormalities without the need for sedation. Your spine surgeon may also advise your pediatrician to obtain an ultrasound of the kidneys or a cardiology (heart) consult. Because the kidneys and heart are formed at the same time as the vertebrae, something that affects the spine may likely affect the other organs. Children with congenital scoliosis have a 25% chance of having an anomaly in the urologic system (kidneys, bladder) or a 10% chance in the cardiac (heart) system. The child's limbs should be examined for any musculoskeletal abnormalities, such as a clubfoot or malformed hand/arm.



Prognosis

When your child's congenital spine anomaly is first diagnosed, no one will know exactly how much the spine deformity will progress as the child grows. There are some clues, however. Anomalies in the thoracic spine tend to progress more. Multiple fully-segmented hemivertebrae on the same side of the spine also tend to progress more. A hemivertebra opposite a set of fused vertebrae (Figure 2, 'Bar') is the most likely combination to progress as the child grows. Because the most rapid period of spinal growth is in the first 5 years of life, and then at adolescence, these are the two times when the congenital curvature must be monitored most closely.

Figure 3 – CT 3D reconstruction showing a T12 “butterfly” vertebra (cleaved in center) and right L3 hemi-vertebra.

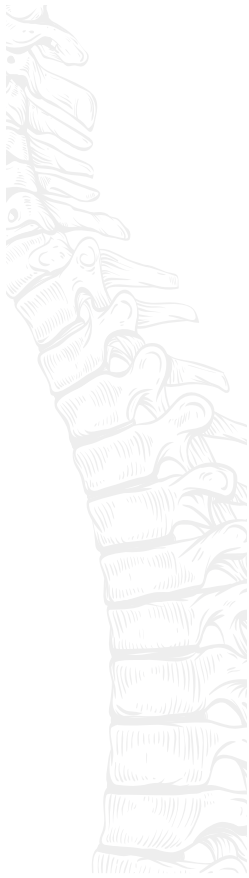Neuromuscular Scoliosis



Introduction

Neuromuscular disorders affecting the spine can result from *neuropathic* (nervous system-related) disorders like Cerebral Palsy (CP), Spinal Muscle Atrophy (SMA), or trauma to the spinal cord; or *myopathic* (muscular system-related) disorders like Muscular Dystrophy, Poliomyelitis, or Arthrogryposis. Children with spina bifida can also develop varying forms of spinal deformity depending on the level of involvement. The deformity may affect the cervical, cervico-thoracic, thoracic, thoracolumbar or lumbar spine and/or combination of these, depending on the underlying neuromuscular condition and level of neurologic defect. It may be predominantly scoliosis, kyphosis, lordosis or a combination. Unlike the other types of scoliosis, treatment of neuromuscular scoliosis is very unpredictable, because the nature of progression for each curve is highly dependent on the underlying neuromuscular diagnosis.





Evaluation

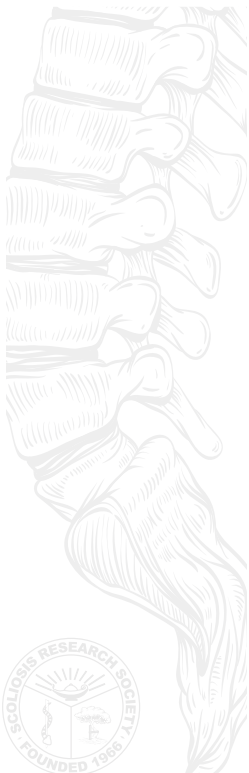Neuromuscular scoliosis is usually first identified during a standard physical examination by a pediatrician, noticed by a child's parents, or during a full workup for the child's neuromuscular condition. The physical examination will be followed by a series of x-rays, which allow for a more exact measurement of the possible presence and severity of one or more curves. A full neurologic exam of the back and limbs will be performed to ensure that no other spinal conditions are present and that the spinal cord is not affected by the presence of the abnormal curvature. Occasionally, a spinal MRI will be obtained in addition to the spinal X-rays.

Prognosis

Because neuromuscular conditions are so varied in their clinical presentation, the actual *pathophysiology* (i.e. the set of events or process that ultimately brings about a condition) of scoliosis in these conditions is also varied. However, there are several features that are common across many, if not all, of the predisposing conditions.

Children with neuromuscular scoliosis usually do not experience any pain from the condition. The earlier the curve develops in neuromuscular scoliosis, the more likely it is to progress to a more severe curve. Likewise, the more severe a curve is when it is first detected, the faster it will progress, on average. Neuromuscular curves often cause pelvic obliquity, a condition where the child's pelvis is unevenly tilted, making sitting difficult in patients who do not walk. Many children with neuromuscular scoliosis have poor balance and poor coordination of their trunk, neck, and head. There is also a high frequency of concurrent kyphosis, which is an abnormal forward-bending curve of the spine. The curves in almost all of the predisposing conditions have a high rate of progression, and many children will therefore require surgery at some point.

Syndromic Scoliosis



Introduction

There are some specific syndromes that can include a scoliosis deformity. These syndromes include Marfan syndrome, Ehlers-Danlos syndrome, Osteochondrodystrophy (dwarfism), Neurofibromatosis, Noonan Syndrome, VATER Syndrome, Angelman Syndrome, Rett Syndrome, and many others.

Evaluation

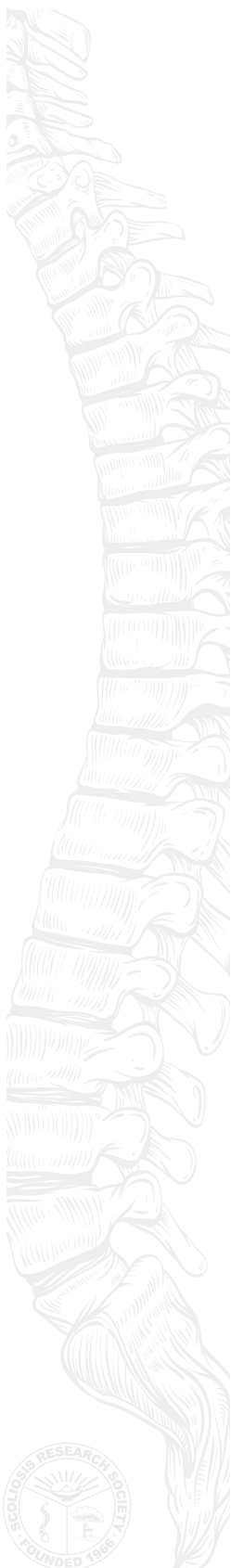When a child is diagnosed with one of these syndromes, screening for scoliosis will begin fairly early. Examinations of the back, including X-rays, will be done on a regular basis.

Prognosis

Because syndromes are so varied, the curves that they cause in the spine progress at varied rates. Close assessment and follow-up with your pediatrician and your spine surgeon will help to manage effects of scoliosis and ensure that intervention is arranged when necessary.



Thoracic Insufficiency Syndrome



Introduction

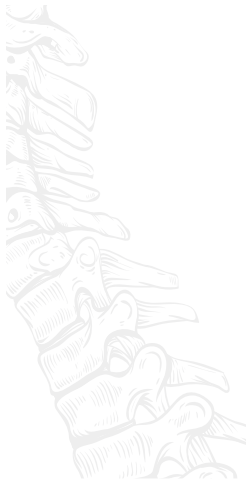Thoracic insufficiency syndrome results from a primary chest wall problem and/or scoliosis that significantly limits a child's lung development. The thorax, which includes the spine, the rib cage, and the sternum, is the engine of respiration. It must have adequate space for the lungs to grow and it must be able to change that volume for breathing (respiration) to occur. In thoracic insufficiency syndrome, the three-dimensional deformity of the thorax can limit its important role as a respiratory engine. This can affect the spine and rib cage in many different ways, but the common problems are deficiencies in thoracic volume, symmetry, and function.

Most of the work of breathing is done by the diaphragm muscle, which is the thin muscle at the base of the thorax underneath the lungs. When the diaphragm contracts, the volume of the thorax increases with the air brought into the lungs. When the diaphragm muscles relax, air is forced out of the lungs. Another important part of the act of breathing is the outward expansion of the chest wall itself from the many small muscles between the ribs. For the thorax to have optimal efficiency as a respiratory pump, it must have ideal volume for age, the ribs need to have a symmetrical shape in order for them to move properly, and the diaphragm muscle must be properly anchored at the base of the chest. In congenital scoliosis, there can be missing or fused ribs. When there is an absence of ribs of the chest wall, the underlying lung collapses inward with breathing without effectively expanding. In fused ribs and congenital scoliosis, the concave side of the curve usually contains a lung constricted by the fused ribs. Additional loss of thoracic volume may be seen in scoliosis when the curve rotates the spine into the chest on the convexity of the curve, often protruding deeper into the chest in a deformity called lordosis (sway back), flattening the chest with loss of thoracic volume. In this instance, the ribs cannot move well enough to help with respiration, and breathing becomes totally dependent on the diaphragm muscle. Increasing deformity of the thorax results in greater volume loss and may lead to breathing problems to a point that a child may require oxygen or even ventilator support.

There are conditions that can affect thoracic volume without necessarily causing spine deformity. One example is Jeune syndrome, in which there is a severe narrowing of the chest due to the failure of the ribs to grow. This causes a hypoplastic (small) thorax, constricting the lungs from each side because of the narrow rib cage. Hypoplastic thorax can also be caused by a compromise in the height of the thorax in conditions such as Jarcho-Levine syndrome. Both of these syndromes are rare, but may have a high mortality rate from respiratory problems early in life.

Evaluation

Unlike the diagnosis of scoliosis, which is made based solely on measurements of angulation of the spine on X-ray, the diagnosis of thoracic insufficiency syndrome is complex, requiring detailed history, physical examination, laboratory studies, X-rays, CT scans, as well as pulmonary function studies, if obtainable. It is important to diagnose thoracic insufficiency syndrome in young scoliosis patients early, and its possible your spine surgeon may refer you to other specialists to assist with this diagnosis.



Prognosis

Thoracic insufficiency syndrome impacts the development of a child in two distinct ways. The first is the inability to support normal respiration. A thorax in early stages of deformity from scoliosis or from fused or absent ribs may have a minor degree of inhibition of respiration, and the patient may appear normal. As the deformity worsens, the respiration can become more labored with increased breathing rate and the inability to keep up with playmates in play activities. When thoracic volume is severely decreased and the diaphragm is the only source of respiratory effort, children may need respiratory aides such as supplemental oxygen or additional respiratory support. The second component of thoracic insufficiency syndrome is the inability of the thorax to support lung growth. Early in life, a small thorax may be adequate for an infant, but if the child grows without the thorax enlarging the lungs remain small. With additional growth, the lung function becomes inadequate as child-size lungs attempt to provide enough oxygen that a teenager would require.

Non-Surgical Management



Introduction

There are several treatment options available to children with early onset scoliosis. It is important to recognize that these treatments are individualized for each patient. Several factors are involved in this decision-making process and your spine surgeon is well-suited to help guide you towards the optimal treatment for your child. In addition, not all treatment options are FDA-approved; however, they are sometimes used “off label” if directed by a physician. This section details the different options available for the treatment of early onset scoliosis. There often are several possible treatment options for your child; your surgeon can discuss these with you in relationship to the specific aspects of his or her case.

Observation

Observation is usually the first method of treatment for a young child with a spinal deformity. The physician will first need to determine if the curvature is progressing -- that is, getting worse. Some children will have a curvature of their spine that is stable and unchanging, whereas other children will have a curve that keeps progressing. Just because your spine surgeon is “observing” your child does not mean that he/she is not treating them. During this period of time, not only will your child’s surgeon look for changes in the curve, but they will probably order some special tests to evaluate further the child’s condition and have you see some other doctors. These tests may include an MRI study or a CT study (different kinds of diagnostic imaging). Your child may be referred to other specialists, such as a geneticist, cardiologist, or pulmonologist to make sure there are no other problems in other parts of the body.

Your spine surgeon will probably want to see your child regularly and have new front-and side-view X-rays taken. They will then measure the curves and compare them with the previous X-rays, as well as the X-rays from the child’s first visit. It is ideal to have all of the X-rays done at the spine surgeon’s office so that he/she can have similar types of X-rays for comparison and maintain your child’s record. The surgeon will probably continue to observe your child’s curves as long as there is no drastic increase in the size of the curve. In some cases the curve will improve or even resolve (as in infantile scoliosis). If your spine surgeon finds progression of the curve, or determines that progression is highly likely, a different form of treatment will need to be started. He/she may want to obtain bending X-rays of the spine to assess flexibility and help determine the next steps in treatment.



Bracing

If the curve is progressive, and your child is still growing, your surgeon may want to place your child in a brace. If the curve is rigid and does not correct (get smaller) on the bending X-rays, a brace will do little good. Rarely does a brace permanently correct scoliosis; instead the goal of bracing is to allow the child to grow before a surgical procedure is done. It must be re-emphasized that the purpose of the brace is to slow the inevitable progression of the curve, not to correct the curve.

The brace that your doctor prescribes may depend on your child's age and the center you visit. There are several types of braces that have the same success rates, but your doctor will select one based on his/her experience with the different devices. The Kalabas brace has several straps that are applied over the shoulder and bend the child in the opposite direction of the curve (Figure 4). The Wilmington brace is a custom-molded thoracolumbosacral orthosis that has molds to push and correct the curve (Figure 5).

fig.4

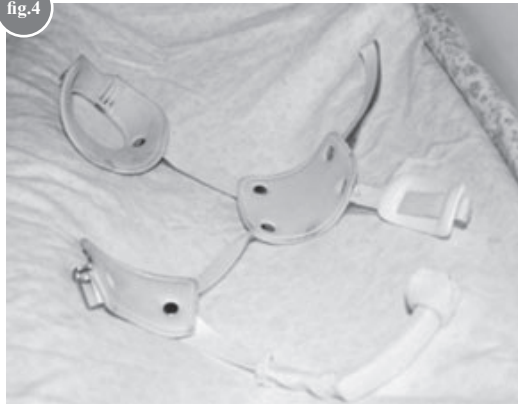

Figure 4 – The Kalabas brace has several straps that are applied over the shoulder and bend the child in the opposite direction of the curve

fig.5

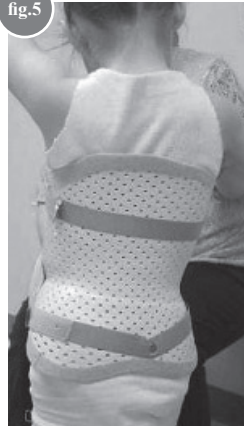

Figure 5 – The Wilmington brace is a custom-molded thoracolumbosacral orthosis that has molds to push and correct the curve.

fig.6



Figure 6 – Boston brace or thoracolumbar sacral orthosis (TLSO)

fig.7

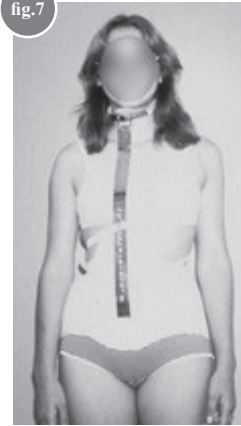
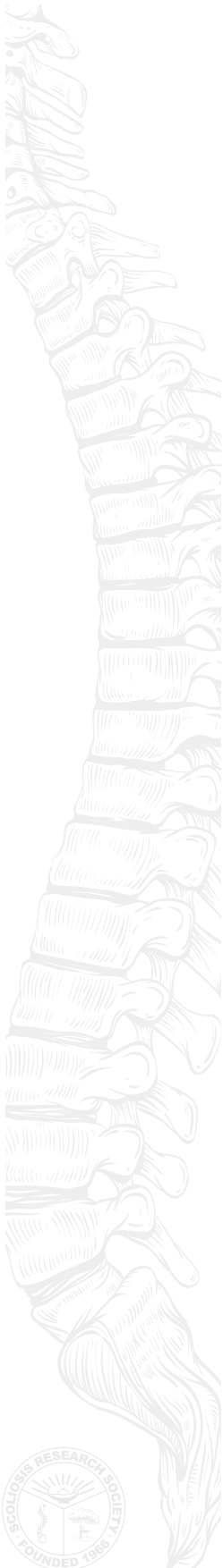
Figure 7 – The Milwaukee brace, with an extension to the chin, is able to control curves in the top part of the spine.





Braces may not be effective in every child for various reasons. The curve may be stiff and resistant to correction. Braces also have a more difficult time controlling kyphosis (rounded back) and lordosis (sway back). Since most braces work on the curve by putting pressure on the rib cage, patients must be able to tolerate the pressure on their ribs and not have any underlying pulmonary problems that would be negatively affected by the brace.

Cast Treatment

A few centers treat young children with a body cast (Figure 8). Placement of the cast on the child may require general anesthesia to increase flexibility of the curve and make the child more comfortable during the application. The cast is generally changed every two to four months, usually under an anesthetic. Cast treatment can offer superior curve management, at the cost of its inconvenience (cannot be removed for bathing).

Serial casting (one cast after another, changing at regular intervals to allow for growth) can be used to delay the need for bracing by correcting the deformity enough to allow bracing to then be re-instituted. Since a cast can be considered a full-time brace that can't be removed, many parents find it preferable to braces, eliminating the problems of compliance and the difficulties of donning braces in uncooperative young children.

Cast treatment can become a definitive method of management rather than simply a delay tactic. In general, small curves which are treated at a young age can often be effectively treated with cast application.

Casting in children under 2 years of age, where the goal is curing the scoliosis, requires cast changes under anesthesia every 2-3 months (minimum 5 casts) with the goal of achieving a straight spine. Despite the extensive casting a brace will still be needed after the casting treatment. Children over age 2 require cast changes every 3-4 months. Older children demonstrating "recurrence" can be re-casted for four months to re-correct the deformity before continuing with brace management.

Traction

Treatment for patients with a progressive deformity who are not candidates for bracing or casting can be more difficult, for example those with weakness, skin or chest wall intolerance, mental retardation, or with large and stiff curves that do not correct much during serial casting. In these instances, halo-gravity traction is a method to achieve deformity correction, and indirectly, improve breathing mechanics. The traction method of treatment has recently regained popularity in some centers.

A halo (metal ring around the head) is applied under general anesthesia. Multiple pins attach the ring to the patient's skull. The halo is not painful and is well tolerated after the patient becomes used to its presence. Traction is applied the following day with the use of ropes, pulleys, and weights or springs that can be applied to the child's bed or a wheelchair. Some patients can be treated as outpatients if the family is comfortable. The children are followed with serial X-rays after successive increases in the weight of the




Figure 8 – Patients treated with scoliosis casting. Holes are cut along the chest and abdomen to allow for normal breathing and eating. Shoulder straps are optional.





traction. Once the spine has shown the maximal amount of improvement, your surgeon will decide the next steps in treatment. Halo traction is usually used as a precursor to surgery.

Exercise Treatment

Scoliosis Specific Exercises (SSE) have received a lot of attention in the media recently. There is hopeful optimism that some of these regimens might help patients with scoliosis, but to date there is not enough evidence to recommend them for every patient. Your doctor can discuss this with you and determine any role for SSE based upon your child's specific case.

Surgical Treatment



Introduction

An operation is sometimes necessary to address spinal deformity in the young child, and the decision to do these procedures is based on many factors. If the child's curve has shown progression despite bracing or casting, surgery must be considered. The dilemma faced by the surgeon is how to stop the progression of a curve without adversely affecting future growth. Sometimes this is unavoidable, as most operations work by stopping abnormal spinal growth in a procedure called spinal fusion.

In Situ Spinal Fusion

Spinal fusion is a procedure performed to stop growth of the spine. It can be done from the back (posterior) or through the chest and/or abdomen (anterior). The joints of the spine are removed, and a bone graft is placed; when the bone heals there will be a fusion mass, or one solid piece of bone. The goal is for the many vertebrae of the spine to become one segment and stop growing crooked. In situ fusion means that the curve will be fused "where it is" with little or no correction of the spine. Sometimes instrumentation (rods, hooks, and screws) may be placed to help straighten the spine slightly and act as an internal brace for the bone graft that will form the fusion mass. When implants are not used, usually in young children, the child may need to wear a brace following the operation.

The goal of an in situ spinal fusion is to address the problem early, before it becomes a serious deformity. For example, if a spine surgeon sees a child with a 40° curve that has a high chance to progress, he/she may elect to perform a limited spinal fusion to prevent the curve from getting any bigger. It is generally a safer procedure than those that correct the curvature of the spine. The results of a procedure to correct the curve at a young age may be unpredictable, as continued growth of the spine in other areas can cause the curve to progress or rotate (twist around). Spinal fusion is not always a good option for every patient with early onset scoliosis. Because spinal fusion basically stops the growth of one part of the spine, it can restrict growth of the thorax resulting in thoracic insufficiency.

Hemi-epiphysiodesis

This surgical procedure is aimed at stopping abnormal growth on one side of the spine with the hope that continued growth on the other side will result in correction of the curve over time. Every curve has a concave and convex side (Figure 9). If the growth centers are removed and spinal fusion is performed on the convex side, the concave side might continue to grow, possibly improving the curve. As noted, these procedures can be unpredictable in young children with abnormal vertebrae in their back.

Hemivertebra Resection





Some young children with scoliosis may have abnormally shaped vertebrae in their back that causes the curve. Normal vertebrae are shaped like rectangles. A hemivertebra is shaped like a triangle (Figure 10). When this hemivertebra is located at the bottom of the spine it can tilt the base of the spine and cause the child lean to one side. In other parts of the spine, depending on the number of hemivertebrae present, severe deformity can develop. Depending on your child’s situation, this hemivertebra may be removed from the front, back, or both parts of the spine. Once the hemivertebra is removed the vertebrae above and below it are fused together, often with instrumentation. Most children will wear a brace or cast after the operation until the spine heals. This operation has inherent risks involved, including bleeding and neurologic injury, but good spinal correction is often achieved.

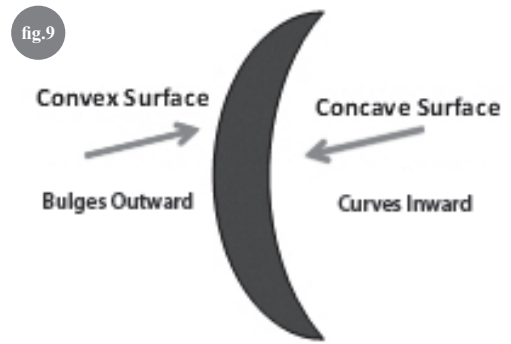


Figure 9 – Hemi-epiphysiodesis is aimed at stopping abnormal growth on one side of the spine with the hope that continued growth on the other side will result in correction of the curve over time.

Growth Friendly Surgery

In the past, spinal fusions were the usual treatment for early onset scoliosis. It is now understood that early fusion of the thoracic spine will limit the growth of the lungs as well as the spine and can lead to severe respiratory problems. Growth friendly surgical procedures, that correct the deformity while avoiding long fusions of the spine, are being developed and refined. Today there are a number of possibilities, each with their own benefits and disadvantages. In general, the type of surgery may be classified as (1) Distraction-Based, (2) Guided Growth, and (3) Compression-Based.

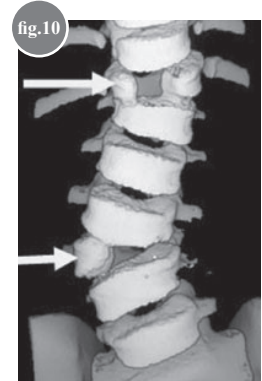


Figure 10 – Hemivertebrae is noted by the bottom of the two arrows.

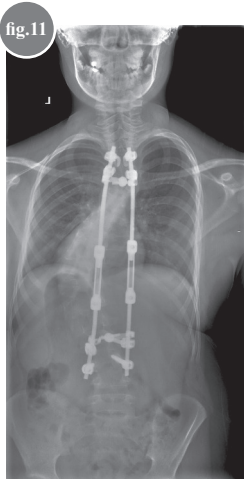


Figure 11 – Growing rods are a spine-based system where the curve is spanned by one or two rods under the skin to avoid damaging the growth tissues of the spine. The rods are attached to the spine above and below the curve with hooks or screws at either end of the rod.

Distraction-Based

Distraction-based procedures include expandable spinal implants that work by controlling the spinal deformity, while still allowing the spine to grow until the child reaches an appropriate size or age for a more permanent solution, like spinal fusion. There are several different types of posterior distraction systems. The rods are periodically lengthened by relatively minor procedures usually performed every 6 months.

Growing rods are a spine-based system where the curve is spanned by one or two rods under the skin to avoid damaging the growth centers of the spine. The rods are attached to the spine above and below the curve with hooks or screws at either end of the rod (Figure 11). Limited fusion is performed at each of the hook/screw foundation sites. The curve can usually be corrected by fifty percent at the time of the first operation. After the rods are implanted, patients are prescribed a special brace to wear for several months. The child then returns every six months to have the rods “lengthened” until the spine is closer to maturity. This



is usually an outpatient procedure performed through a small incision. When the child becomes older and the spine has grown, the doctor will remove the instrumentation and perform a formal spinal fusion operation. In the past, this procedure had a very high complication rate, most of which were related to the instrumentation (hook dislodgement, rod breakage). Newer techniques are more promising but treatment with growing rods remains a long, difficult therapy for the child.

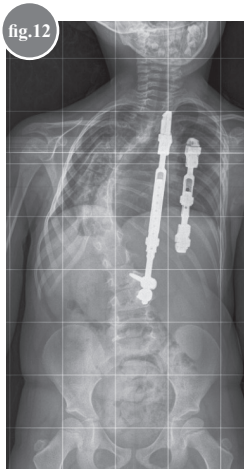


Figure 12 – Rib-based devices are placed under the scapula (shoulder blade) and are attached to the ribs near the neck and continue down to either the ribs, spine, or to the pelvis near the waist. This is an example of a rib-rib device and a rib-spine device.

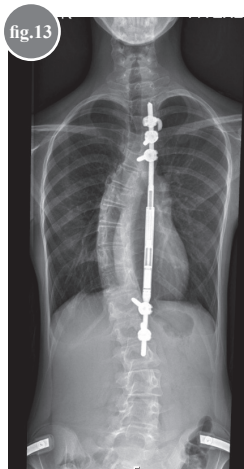


Figure 13 – Magnetically Controlled Growing Rod (MCGR) in a patient with idiopathic early onset scoliosis.

Rib Based Systems, such as Vertical Expandable Prosthetic Titanium Rib (VEPTR), are systems used for treatment of thoracic insufficiency syndrome in skeletally immature patients. Thoracic insufficiency syndrome (TIS) is usually associated with uncommon three-dimensional deformities of both the spine and rib cage. Several types of rib-based expansion thoracoplasty operations can be used for different types of deformities to gain chest volume (to allow for growth of the underlying lungs) while indirectly correcting the scoliosis without spine fusion. This surgery can be extensive; devices are placed under the scapula (shoulder blade) and are attached to the ribs near the neck and continue down to either the ribs, spine, or to the pelvis near the waist (Figure 12). This helps to stabilize the surgically expanded chest wall constriction (expansion thoracoplasty). To keep up with

a patient's growth, the devices are expanded twice a year in outpatient surgery through small incisions. Currently, there are a number of institutions offering rib-based surgery. Your child's spine surgeon can advise whether your child's condition is appropriate for this treatment option and to provide referral information, if needed. Some centers are using the rib-based devices as a means to straighten the spine indirectly via the ribs and chest wall.

Hybrid growing Rods

This is a newer technology that uses growing rod technology. Here the ribs, not the spine, are used as the upper anchor. The fusion of the upper portion of the spine is avoided.

Magnetically Controlled Growing Rods (MCGR)

Growth rods are currently the most commonly used distraction-based technique and have the advantage of not interfering with the normal spinal growth and may even have a potential for growth stimulation beyond the normal growth rate. However, the technique requires frequent surgeries for construct lengthening to keep up with normal spinal growth and to maintain scoliosis curve correction. Multiple surgeries, mostly through the same incision site, leave the skin tissue susceptible to infection and other skin problems. Implant related complications are the most common complications in growth rod surgeries. These include rod fracture, anchor failure, or prominent implant, which can cause skin breakdown and even infection. Among the implant-related complications, rod fractures are the most common problem.





The idea of non-invasive multiple lengthening without the need for anesthesia and open surgery is appealing given the direct relationship between high complications and repeated surgeries. These devices allow for lengthening to be performed in the doctor's office. It is composed of an implantable rod, an external remote controller (ERC) and accessories. The titanium rod includes a telescopic actuator portion that holds a small internal magnet. Rotation of the magnet remotely by use of the ERC causes the rod to be lengthened or shortened. The rod is implanted and secured using standard fixation components, such as hooks and/or pedicle screws as anchors. Magnet driven rods are now available in many countries and preliminary results have shown them to be able to reduce morbidities, cost, and decrease stress for patients and parents. They have been implanted in cases of both idiopathic (Figure 13) and neuromuscular scoliosis.

Guided growth

These techniques involve instrumentation that guides spinal growth in a correct direction. Unlike distraction techniques, repeated surgeries are not required

The Luque Trolley uses wires to allow the spine to grow in the desired direction as the wires slide along contoured rods. In the Shilla technique initial correction is obtained by instrumentation and fusion at the apex, or most deformed portion of the spine. Specially designed screws are placed at the ends of the deformity and slide along the contoured rods guiding the direction of the spine as it grows. These children are usually placed in a special brace for 3 months after the surgery.

Compression-Based

Compression-based systems are intended to produce relative growth inhibition on the convex side of the curve. These techniques can be used in children who are still growing, have a progressing deformity that measures less than 35 degrees, and who are able to tolerate open or endoscopic exposure of the spine. By placing special vertebral body staples or tethers on the convex side of the curve, growth is inhibited on that side. The idea is that the scoliosis may then correct through more growth on the concave side of the curve.

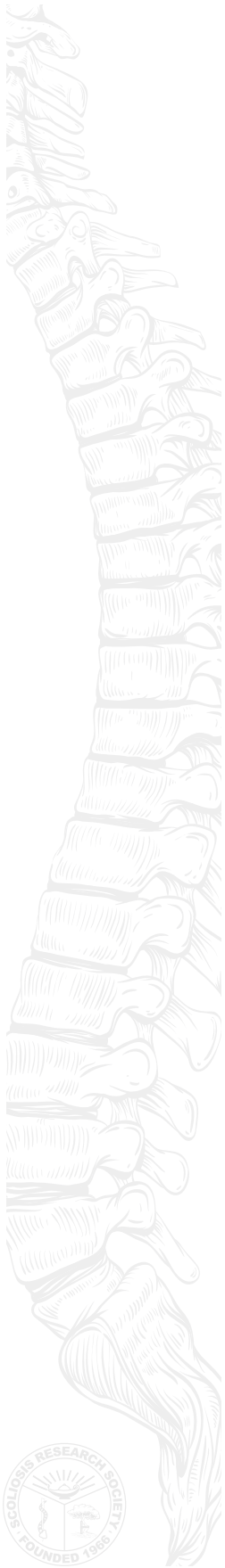Fusion with Instrumentation Surgery

In some cases, fusion with instrumentation surgery will be advised. This may be indicated when the child is closed to the end of growth or when co-existing medical problems make the growth friendly procedures, which often require multiple surgeries, too dangerous. In most cases this will involve posterior spinal instrumentation and fusion of the entire deformity. When a significant amount of growth remains, a posterior fusion may result in a twisting or "crankshaft" deformity as the growth of the anterior or non-fused front of the spine is tethered by the fused posterior portion. To avoid this problem an anterior fusion (the front of the spine is fused by removing the discs and inserting bone graft) is often performed at the time of the posterior procedure in selected children.

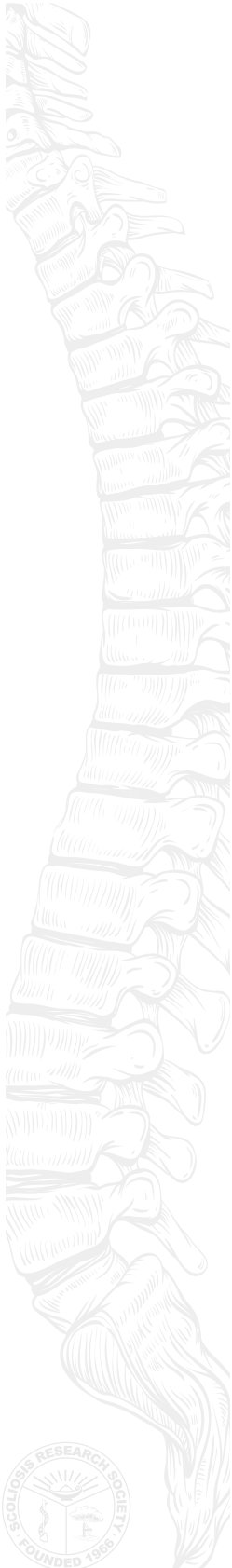Summary



Early onset scoliosis encompasses a variety of patient types, all of whom have a curvature of the spine. The cause of an individual's scoliosis, as well as the size and nature of the curve, will determine the likelihood of progression and the need for treatment. Bracing, cast treatment, growth-sparing surgery, and spinal fusion are all options for treatment. Your doctor can help determine the best treatment for your child.



Your support can change the lives of others with spinal deformities



Please consider a donation to SRS.

100 percent of all contributions and donations to the Scoliosis Research Society's (SRS) Research, Education Outreach (REO) Fund are used entirely for research, outreach programs, and educational scholarships and fellowships seeking improved treatments, the causes and possible prevention of spinal deformities. Operating funds for SRS come from membership dues, educational meetings and courses, publication sales and other sources.

With your support, SRS can continue to support and offer necessary educational opportunities, beneficial research grants and maintain effective advocacy efforts that will change the lives of those living with spinal deformities.

If you would like to make a donation to the Scoliosis Research Society, please fill out the form below and mail it to:

Scoliosis Research Society
555 East Wells Street, Suite 1100
Milwaukee, WI 53202-3823 USA

Please make checks payable to Scoliosis Research Society.

If you would like to make your donation online, please go to www.srs.org/professionals/research-and-journal/donate

YES! I would like to donate to the Scoliosis Research Society (SRS) to help continue in fulfilling its mission to improve the lives of patients with spinal deformities!

Enclosed is my gift of: \$10, \$20, \$35, \$50, \$100, \$150, Other _____

This gift is (in honor/in memory) of _____

Please make checks payable to Scoliosis Research Society. If you would like to make your donation online, please go to www.srs.org/professionals/research-and-journal/donate

Credit Card Information

Name

Address City State Zip Country

Phone Email

Visa, MasterCard, American Express, Discover

Card Number

Exp. Date (MM/YY) Security Code

Signature

Contributing to the REO Fund

Thank you for considering a donation to the Scoliosis Research Society. All donations made to SRS through the REO Fund are recognized through the SRS Levels of Giving. Levels of Giving can be achieved over a lifetime. Recognizing that donors based in the U.S. receive significant tax benefits for charitable donations; corresponding recognition levels have been established for international donors. The REO Fund provides donors the opportunity to donate through various options, from individual donations, pledged giving over five years or even deferred gifts.



LEVEL OF GIVING	DONATION AMOUNT	
	UNITED STATES	OUTSIDE U.S.
CONTRIBUTING	\$100 - \$4999	\$50 - \$2499
SUSTAINING	\$5000-\$9999	\$2500-\$4999
BENEFACTOR	\$10,000-19,999	\$5000-\$9999
PRESIDENTS	\$20,000-\$39,999	\$10,000-\$19,999
PRESIDENTS ELITE	\$40,000-\$99,999	\$20,000-\$49,999
FOUNDERS	\$100,000-\$499,999	\$50,000-\$249,999
LEGENDS	\$500,000-\$999,999	\$250,000-\$499,999
LEGENDS ELITE	\$1 Million or more	\$500,000 or more

Pledges can be spread over a maximum of five years per level. For example, members outside the U.S. can reach Benefactor Level with payments of \$1,000 per year for five years or \$2,000 over five years to achieve Presidents level.

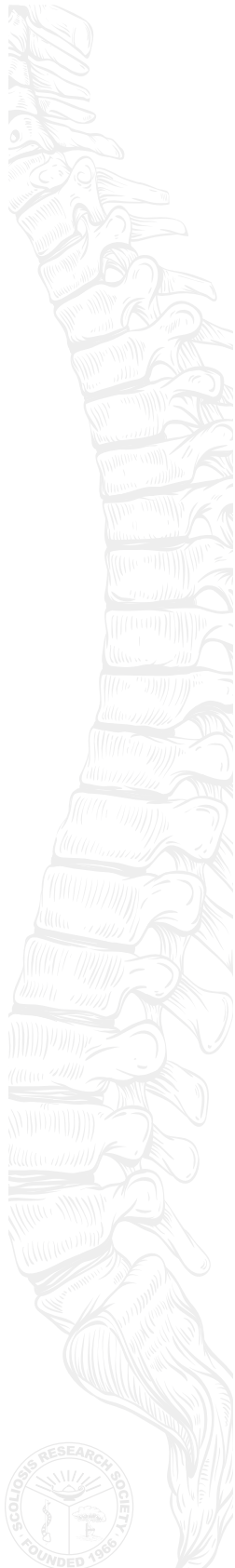
Individual gifts can be made at any time, in any denomination and will accumulate over the span of the donor's life. Levels of Giving are achieved as the donor continues to give.

Deferred giving A U.S. life insurance gift of \$100,000 will earn the donor a place in the Founders Recognition Level.

The SRS is a 501(c)(3) organization, tax identification # 23-7181863. Your gift to the SRS REO fund is fully tax-deductible to the extent allowed by law.



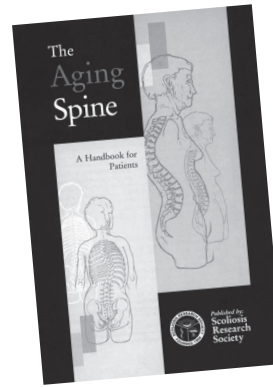
Other brochures available through the Scoliosis Research Society



Spinal Deformity: Scoliosis and Kyphosis

A Handbook for Patients
12-page brochure discusses signs and causes of scoliosis and kyphosis, indications for treatment,


treatment options, commonly asked questions and a glossary of terms. Illustrated.



Aging Spine A Handbook for Patients

An 8-page brochure discusses causes and treatments of osteoporosis and compression fractures, and osteoarthritis and other degenerative

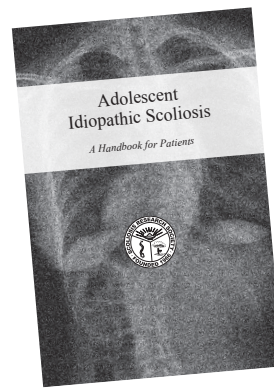
conditions of the spine.



Spinal Deformity: Congenital Scoliosis and Kyphosis

A Handbook for Patients and Parents
12-page brochure discusses signs and causes of congenital spinal deformities,

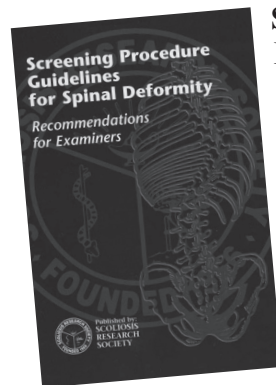
associated conditions, treatment options, and a glossary of terms. Illustrated.



Adolescent Idiopathic Scoliosis A Handbook for Patients

A 12-page handbook that discusses the basics of Adolescent Idiopathic Scoliosis

and treatment options, as well as a glossary of terms and frequently asked questions. Includes photographs.




Screening Procedure Guidelines for Spinal Deformity: Scoliosis and Kyphosis

Recommendations for Examiners
7-page brochure covers reasons, organization and procedures

for spinal screening. Signs of spinal deformity, as seen in both standing and forward bending positions, are illustrated and discussed. Includes sample screening form.

To order additional brochures please contact: info@srs.org





Phone: (414) 289-9107
Fax: (414) 276-3349
Email: info@srs.org
Web: srs.org

Dedicated to the optimal care of patients with spinal deformity.

SCOLIOSIS RESEARCH SOCIETY | 555 EAST WELLS STREET, SUITE 1100 | MILWAUKEE, WI 53202-3823 USA